

OWNER

Phone

Kevin Ladouceur
ADDRESS (Street & No., City, Zip Code)
147 Fitch Field St, Ft. Mill, SC 29504

Animal Registered Name
Q.V. Silvercobb Northern Light
Breed/Variety
American Quarter Horse

CANINE EYE REGISTRATION FOUNDATION

Nick Whelan, Diplomate, ACVO
MCO of Guelph, Ontario, Canada N1L 1T4
(519) 823-9830

For litters, add number.

I hereby declare that the animal submitted for exam is the animal described above. Furthermore, I declare I am the owner or agent of the owner of this animal.

Signature
Kevin Ladouceur

PRESS FIRMLY.
FILL COMPLETELY.

SEX
Male Female

BIRTH DATE
Jan DAY YEAR
Feb DAY YEAR
Mar DAY YEAR
Apr DAY YEAR
May DAY YEAR
Jun DAY YEAR
Jul DAY YEAR
Aug DAY YEAR
Sep DAY YEAR
Oct DAY YEAR
Nov DAY YEAR
Dec DAY YEAR

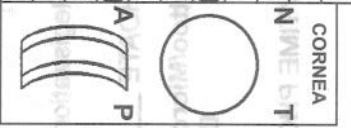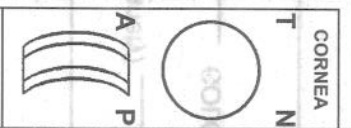
FOR CERF USE ONLY
BREED
COLOR

EXAM DATE
Jan DAY YEAR
Feb DAY YEAR
Mar DAY YEAR
Apr DAY YEAR
May DAY YEAR
Jun DAY YEAR
Jul DAY YEAR
Aug DAY YEAR
Sep DAY YEAR
Oct DAY YEAR
Nov DAY YEAR
Dec DAY YEAR

REGISTRATION NO. grid with columns for registration numbers 0-9.

RIGHT EYE GLOBE LEFT EYE
microphthalmos
dry eye
glaucoma
EYELIDS
ectropion
entropion
distichiasis
ectopic cilia
eury/macro blepharon
CORNEA
dystrophy -- epithelial/stromal
dystrophy -- endothelial
inherited pannus
exposure/pigmentary keratitis
UVEA
iris/ciliary body cyst
iris coloboma
iris hypoplasia/sphincter dysplasia
pigmentary uveitis
uveal melanoma
persistent pupillary membranes

RIGHT EYE FUNDS LEFT EYE
retinal atrophy - - generalized
retinal atrophy - - suspicious
retinal dysplasia/retinopathy
choroidal hypoplasia
staphyloma/coloboma
retinal detachment
optic nerve coloboma
optic nerve hypoplasia
micropapilla
OTHER UNLISTED CONDITIONS
OTHER conditions suspected as not inherited
NORMAL

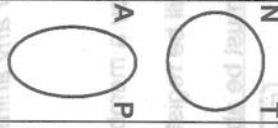
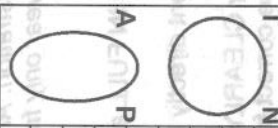


Endothelial Pigment/no PPM
Iris Sheets
Iris to Cornea
Iris to Lens
Iris to Iris

Iris to Iris
Iris to Lens
Iris to Cornea
Iris Sheets
Endothelial Pigment/no PPM

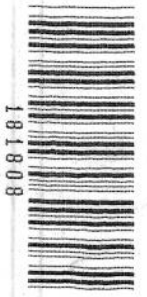
CATARACT
Diff. Inter. Punc.
Punc. Inter. Diff.

CATARACT
Diff. Inter. Punc.
Punc. Inter. Diff.



ant. chamber
syneresis
significance of above punctate cataract unknown
subluxation/luxation
WITREOUS
PHPV/PTVL
degeneration
ant. chamber
syneresis

I certify that I have performed this ophthalmic examination using pharmacologic mydriasis, ophthalmoscopy, and biomicroscopy.
Signature
Date



Diplomate, American College of Veterinary Ophthalmologists
COMMENTS
ACVO #

Actual vessels look -
normal
range for normal

Owner Copy